ISSN : 0974-6781

www.jdionline.org



Journal of Dental Implants

Official Publication of
the Indian Society of Oral Implantologists

Volume 12• Issue 1• January-June 2022

Wolters Kluwer

Medknow

ORIGINAL ARTICLE

Marginal bone change, survival and biological complications around dental implants with a platform switched, Morse taper connection, and a medium rough surface in a sample of regular compliers patients

Maria Costanza Soldini[1,2], Filippo Trentin[1,2], Ramon Pons Calabuig[3]

ABSTRACT

Context: Marginal bone loss around implants still is difficult to avoid and the great influence of the size of the implant/abutment micro-gap on crestal bone level maintenance have been reported in the literature. The internal conical Morse taper connection has been demonstrated to be an effective system for minimizing inflammatory reactions and maximizing peri-implant bone stability.

Aims: The primary aim of this study was to evaluate the marginal bone change around dental implants with a platform-switched (PS) Morse taper connection and a medium rough surface over a 4-year follow-up period.

Settings and Design: The data for this study were obtained from the clinical records of a private periodontal practice exclusively in Periodontics and Implantology (Vicenza, Italy), treated by one EFP certified periodontist (C.S). The same operator (C.S) performed all the surgeries.

Subjects and Methods: Marginal bone loss around PS Morse taper connection implants was retrospectively analysed on standardized radiographs after 1 year and 4 years from the prosthesis connection.

Statistical Analysis Used: The statistical unit of observation was the single implant. The influence on MBC of the number of implants for the same patient was tested using the Kruskal Wallis non parametric test. The main effects of the follow-up times (T1 and T4) and of each individual factor on MBC were evaluated using the non-parametric Wilcoxon and Mann-Whitney tests respectively. The interaction effect between follow-up time and each individual factor was graphically tested considering the MBC median values in the time level for each factor. Statistical significance was taken at the ≤ 0.05 level (two-sided). All analyses were performed using the STATA/IC for Windows, version 14.2.

Results: Ninety implants were examined in fifty patients. Mean bone change was -0.06 ± 0.31 mm after 1 year and -0.2 ± 0.45 mm after 4 years. The cumulative survival rate at 4 years was 100%, and a low

[1]IDIS (Institute for Dental and Implant Studies), Vicenza, Italy , [2]Private Practice in periodontology and implants, Studio Dentistico SBM, Vicenza, Italy, [3]Maxilonet Barcelona Hospital Universitari Dexeus, Barcelona, Spain

Address for correspondence: Maria Costanza Soldini DDS MSc, Contrà Porti 21, Vicenza, Italy. E mail: mariacostanza.soldini@uic.es

Submitted: 22-May-2021 **Revised:** 13-Jul-2021
Accepted: 23-Nov-2021 **Published:** 16-Jun-2022

Access this article online	
Quick Response Code:	Website: www.jdionline.org
	DOI: 10.4103/jdi.jdi_29_21

This is an open access journal, and articles are distributed under the terms of the Creative Commons Attribution-NonCommercial-ShareAlike 4.0 License, which allows others to remix, tweak, and build upon the work non-commercially, as long as appropriate credit is given and the new creations are licensed under the identical terms.

For reprints contact: WKHLRPMedknow_reprints@wolterskluwer.com

How to cite this article: Soldini MC, Trentin F, Calabuig RP. Marginal bone change, survival and biological complications around dental implants with a platform switched, Morse taper connection, and a medium rough surface in a sample of regular compliers patients. J Dent Implant 2022;12:24-30.

prevalence of implants with clinical signs of mucositis (12.2%) or peri-implantitis (1.1%) was reported. **Conclusions:** In implants where the prosthesis is correctly place and the patient are compliers to their maintenance therapy, the contemporary presence of a Morse taper connection and a switching platform seems to offer good results for the maintenance of peri-implant bone in the short and medium term.

KEY WORDS: Alveolar bone loss, dental implant-abutment design, dental implants, follow-up studies, implant supported

INTRODUCTION

The replacement of missing teeth with an implant-supported restoration is an accepted treatment modality for partially and totally edentulous patients.[1] Despite the high dental implants long-term survival reported in the literature, complications are frequent.[2] This highlights the importance of including the implants success assessment and the measurement of marginal bone loss over time is a sensitive tool for evaluating this clinical performance.[3-8]

Marginal bone loss around implants still appears difficult to avoid because a limited amount of peri-implant bone loss is a biological response to the surgical procedure.[1,7] Minimizing crestal bone loss has remained a constant challenge, and for this reason, modifications to implant design, surface, and abutment connection have been introduced over the last few years to prevent or reduce it.[9-11]

Implant surface topography was identified as one of the most important factors affecting osseointegration. A medium degree of roughness (1.2 Sa) of the titanium implant surface has been demonstrated to induce stronger bone responses than those with a higher one.[11-16]

The great influence of the size of the implant/abutment micro-gap on crestal bone level maintenance has also been reported.[17-20] The internal conical Morse taper connection has been demonstrated to be an effective system for minimizing inflammatory reactions and maximizing peri-implant bone stability.[19-24] Moreover, in this Morse taper connection, the difference in the diameters of implants and abutment creates a switching platform effect which contributes to preserving marginal bone, as demonstrated by several randomized controlled trials reporting minimal peri-implant bone loss.[22-24]

The primary aim of this study was to evaluate the marginal bone change around dental implants with a platform-switched (PS) Morse taper connection and a medium rough surface over a 4-year follow-up period in patients compliant with peri-implant maintenance therapy in a private clinic. The secondary objectives were as follows: (i) to determine the survival and the biological complications of those implants at the end of the follow-up period and (ii) to assess the factors that might contribute to the peri-implant bone loss to achieve a long-term success of implant therapy.

SUBJECTS AND METHODS

Study sample

The data for this study were obtained from the clinical records of a private periodontal practice exclusively in Periodontics and Implantology (Vicenza, Italy), treated by one EFP certified periodontist (C.S). The same operator (C.S) performed all the surgeries.

All available records in the last 5 years of practice were searched by one investigator (MCS) to retrospectively include only partially edentulous patients over 18 years old rehabilitated with CLC Conic™ implants (CLC Conic™, Vicenza, Italy) from June 2012 to November 2013. CLC Conic™ implants (CLC Conic™, Vicenza, Italy) were characterized by sandblasted/acid-etched medium rough titanium surface and a PS and morse taper (MT) connection.

Patients anamnesis was examined to include healthy or periodontal stable patients and we exclude heavy smokers (≥10 cig/day) patients with uncontrolled metabolic disorders, pregnancy, and hematological disorders.[25,26]

Selected patients had a radiological image available at placement, at the prosthesis connection (baseline), 1 and 4 years from the baseline.

Radiograph was examined to assess:

- The quality of the radiographical image
- The distance between the prosthesis and the bone ≥1.5 mm.[27]

Medical records were examined to include implants placed in bone regenerated only with autogeneous graft or/and xenograft.

Compliance with maintenance therapy

Patients included in this retrospective study were all enrolled and followed at least the 80% of the recommended visits of their Supportive maintenance therapy (SPT) with a professional hygienist.

At each (MT):

- Implant was probed in four sites with periodontal probe PCP-UNC 15 (HuFriedy®, Rockwell St, Chicago, IL, USA)
- Plaque presence and bleeding on gentle probing (0.15 N/cm) were recorded[28]
- Parallelized digital radiograph was taken with long-cone parallel technique and a film holder (Dürr Dental AG, Bietigheim-Bissingen, Germany)
- Supragingival debridement by the use of ultrasonic and manual device was provided
- Oral hygiene instruction and re-enforcement were provided
- Cleansibility of the prosthesis by the use of an appropriate interproximal brush (TePe®, Cornaredo [MI], Italy) was checked
- Excess of luting cement and presence of overhanging margins were assessed and removed if present
- One EFP certified periodontist (C.S) revised that all procedure was accomplish.

All patients for whom this information was available were included in this study.

All examinations and data collection were performed by the same examiner (M.C.S).

Study variables

The endpoint variable of the study was the marginal bone change (MBC in mm) that occurred from the baseline to the follow-up time.

The predictor factors of changes in peri-implant bone level were grouped as:

Biological

Gender (male or female), age (years), controlled diabetes type 1 and 2 (yes or no), bisphosphonate therapy (yes or no), and previous periodontal disease (yes or no).

Anatomical

Arch (maxilla or mandible) and position (anterior or posterior).

Implant

Implant diameter (defined as narrow if was = 3.5 mm, wide ≥4.5 mm and standard if was = 4 mm) and implant length (6, 8, 10, 12, and 14 mm).

Surgical

The surgical protocol was recorded as one-stage (non-submerged) or two-stage (submerged); the insertion depth was classified as crestal or subcrestal if implant was placed with the most coronal portion of the platform positioned at least <1 mm below the buccal aspect of the bone crest and postextraction implants (yes or no) were reported. The presence of sinus lift (yes or no), GBR (yes or no), the achievement of primary stability was evaluated during surgery (fixture torque >30 N/cm = yes, <30 N/cm = no).

Prosthetic

Prosthesis type (single crown, multiple fixed bridge, and total fixed), prosthesis' retention (cemented or screwed) and implant loading (immediate: immediately after surgery, early: in the period up to 12 weeks postsurgery and conventional: 12 weeks or more after implant placement).

An implant has been classified as a "surviving implant" when it was still in function, at the end of the 4-year follow-up. Implants which were not still in function at the end of follow-up period would be categorized as failures.

Biological complications (mucositis and peri-implantitis) were assessed each year during the follow-up period. Mucositis was retrospectively diagnosed by the presence of bleeding on gentle probing (0.15 N/cm) assessed during the MT. Peri-implantitis was retrospectively diagnosed according to the last 2017 World Workshop.[29]

Variables considered in our analysis of MBC were: Arch, position, surgical protocol, insertion depth, prosthesis' retention, and only narrow and wide diameters were included.

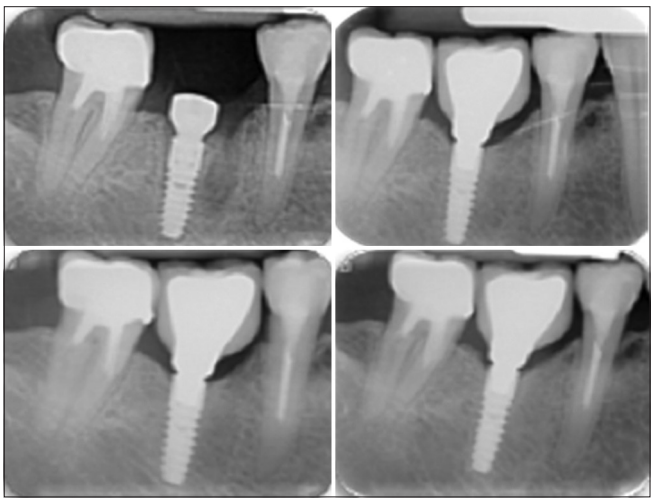

Figure 1: Direct measurements on a standardized, digital peri-apical radiograph at implant placement, baseline, T1 and T4

Table 1: Patients characteristics (*n*=50)

	n (%)
Age (years)	
Mean±SD	54.06±10.24
Median (IQR)	53.5 (47-61)
Gender	
Female	29 (58)
Male	21 (42)
Diabetes	
Yes	2 (4)
No	48 (96)
Previous periodontal disease	
Yes	30 (33.3)
No	60 (66.7)
Bisphosphonate therapy	
Yes	0
No	50 (100)

SD: Standard deviation, IQR: Interquartile range

Table 2: Implants characteristics (*n*=90)

	n (%)
Anatomical factors	
Arch	
Maxilla	47 (52.2)
Mandible	43 (47.8)
Anterior/posterior	
Anterior	14 (15.5)
Posterior	76 (85.5)
Implant factors	
Diameter (mm)	
Standard	28 (31.1)
Narrow	19 (21.1)
Wide	43 (47.8)
Length (mm)	
6	6 (4.6)
8	30 (33.3)
10	37 (41.1)
12	17 (18.9)
14	0 (0)
Surgical factors	
Insertion depth	
Crestal	51 (56.7)
Subcrestal	36 (40)
Post-extractive	
Yes	23 (25.6)
No	67 (74.4)
GBR	
Yes	19 (21.1)
No	71 (78.9)
Sinus lift	
Yes	7 (7.8)
No	83 (92.2)
Primary stability	
Yes	85 (94.4)
No	5 (5.6)
Surgery protocol	
1 stage	50 (55.6)
2 stage	40 (44.4)
Clinical factors	
Mucositis	11 (12.2)
Perimplantitis	1 (1.1)
Prosthetic factors	
Prosthetic rehabilitation	
Single crown	48 (53.3)
Multiple fixed bridge	35 (38.9)
Total fixed	3 (7.8)
Type of retention	
Cemented	34 (37.8)
Screwed	56 (62.2)
Loading	
Immediate loading	0
Early loading	46 (51.1)
Conventional loading	44 (48.9)

GBR: Guided Bone Regeneration

Radiographic analysis

The level of the marginal bone was recorded at the time of implant placement, the prosthesis deliver (baseline), after 1 (T1) and 4 years (T4) [Figure 1], by taking standardized radiographs. Digital radiographs were stored using a digital intraoral imaging system (Dürr Dental AG, Bietigheim-Bissingen, Germany). The stored images were displayed on a monitor and direct measurements were performed using dental imaging software (Dürr Dental AG, Bietigheim-Bissingen, Germany). The length of the implant was used for the calibration of measurements in each radiograph. A mean value was calculated from the mesial and distal bone-level measurements of each implant at the different times. The amount of mean bone change that occurred from the baseline was determined. These measurements could be a positive number (if the crestal bone level was apical to the implant shoulder) zero (if the crestal bone level was located at the implant shoulder), or a negative number (if the crestal bone level was located coronal to the implant shoulder).

RESULTS

Ninety implants were examined in 50 patients; implant number per patient was not found to have any effect on MBC both at T1 (P = 0.41) and at T4 (P = 0.26).

Demographical and clinical characteristics of the sample are shown in Table 1, and the characteristics of the implants in Table 2.

At the 4-year examination interval, 11 implants (12.2%) suffered from mucositis and only one (1.1%) from peri-implantitis.

Table 3: Radiographical bone marginal level (mm) over time (*n*=90)

Time	Mean±SD	Median (IQR)
Baseline	0.16±0.65	0.2 (−0.31-0.61)
1 year	0.22±0.64	0.15 (−0.24-0.57)
4 years	0.36±0.73	0.24 (0-0.71)

SD: Standard deviation, IQR: Interquartile range

The mean and median values of peri-implant bone marginal level during the follow-up period are described in Table 3; during the 1st year, there was a MBC mean value of −0.06 ± 0.31 mm and a MBC median value of −0.04 (IQR = 0.34) mm. Peri-implant bone level alteration was evaluated from the 1st year to the 4th year: The mean value was −0.14 ± 0.39 mm, and the median value was −0.02 (IQR = 0.39) mm. Thus, the mean total bone level change over the 4-year interval amounted to −0.2 ± 0.46 mm and the median value was −0.11 (IQR = 0.58) mm.

The main effect of time was found to be statistically significant ($z = -2.952$, $P = 0.003$; in T1 median = −0.045 IQR = 0.34 vs. in T4 median = −0.11 IQR = 0.58); the main effect of individual factors on the MBC endpoint variable was tested and none of them was significant except for surgical protocol and depth [Table 4]. No effect in terms of the interaction between time and individual factors was detected: The effect of the factors is to be considered constant in the level of follow-up time.

DISCUSSION

The introduction of new implant surfaces and prosthetic connections has added new dimensions to implant dentistry and marginal bone change, universally accepted as being up to 2 mm during the 1st year of function, followed by a maximum of 0.2 mm annually thereafter, may now be subject to question as a reliable success criterion.[5]

Hence, in our study performed with implants with PS and Morse taper connection, a mean bone change of −0.06 ± 0.31 mm after the 1st year and −0.2 ± 0.45 mm after 4 years was observed. In addition, only five implants lost more than 1 mm of peri-implant bone during the 4 years and four implants demonstrated no radiographical bone loss after 4 years.

The high survival rate showed in our study (100%) may be related to the characteristics of the implants included in this study and to the strictly adherence of the patients to the proposed maintenance therapy.

Indeed, the morphologic irregularities that result from this surface treatment promote osteointegration by improving cellular adhesion and proliferation too.[7,9]

Up to now, the histopathological and clinical conditions leading to the development of the peri-implantitis are not completely understood.[30] In a series of studies using a dog model, Hermann showed that the gap between implant and abutment had a profound influence on alveolar bone crest remodelling.[31] Several possibilities could account for this phenomenon and one mechanism may involve bacterial colonization of the micro-gap.[32] Because of this, the epithelium migrates beyond the interface colonized by the bacteria in an attempt to isolate the infection, and bone resorption will occur to ensure the establishment of a soft-tissue attachment to allow for the formation of a 3 mm healthy biological seal around the top of the implant.[33] The findings reported by Koutouzis *et al*. indicated that differences in implant design may affect the potential risk of colonization of oral microorganisms in the implant-abutment micro-gap.[18] In this regard, it should be noted that the tapered interference fit provided by MT connection significantly reduces micro-gap dimensions at the implant–abutment interface. Most bacteria are more than 0.5 μm in diameter while the gap was measured to be <0.5 μm so it was too small for pathogen microorganisms to penetrate.[34] In order to minimize this bone loss adjacent to the two-piece implant, Porter and Lazzara introduced the concept of platform switching. They assumed that the inward repositioning of the implant abutment junction shifts the micro-gap/inflammation away from the crestal bone and allows some additional thickness in the horizontal soft tissue component.[20]

The high success of the implant therapy in terms of survival, bone loss, and biological complication reported in this study is different to that reported in the literature.[27,35] The result of this study cannot be generalized because we include only one type of implant and the sample adhered to a strict maintenance therapy protocol. In our study, the recall interval was at least every 6 months and this interval seems to prevent the incidence of peri-implant diseases.[36] According to the time of the recall visit and the patients' adherence to it, we can classify them as compliers, and we know from the result of Monje *et al*. 2017 that compliance is associated with 86% less conditions of peri-implantitis.[37,38]

In addition, our follow-up is too limited to estimate the true prevalence of peri-implantitis: Derks *et al*. showed that the onset of this disease occurs within 3 years of function, but there is a positive relation with prevalence of peri-implantitis and time of function of the implants.[39,40]

According to the result present by Derks *et al*., we decided to include only the implants where we radiographically assess that the crown restoration

Table 4: Main effect of different factors on marginal bone change by follow-up time

Factors	1 year and 4 years MBC, median (IQR)	*P*
Position		
Anterior	−0.23 (−0.55-0.03)	0.42
Posterior	−0.11 (−0.48-0.18)	
Arch		
Maxilla	−0.14 (−0.56-0.05)	0.26
Mandible	−0.05 (−0.41-0.20)	
Surgical protocol		
2-stages	−0.34 (−0.69-0.01)	0.00
1-stage	−0.02 (−0.25-0.23)	
Depth		
Crestal	−0.00 (−0.34−0.25)	0.03
Subcrestal	−0.15 (−0.60−0.12)	
Prosthesis		
Screwed	−0.09 (−0.40-0,18)	0.10
Cemented	−0.16 (−0.62-0.02)	
Diameter		
Narrow	−0.32 (−0.55-0.04)	0.38
Wide	−0.11 (−0.5-0.18)	

MBC: Marginal bone change, IQR: Interquartile range

margins were positioned >1.5 mm from the crestal bone margins, this to avoid the bias of including implant where peri-implants disease could be the result of a prosthetic misconception, rather than being related with some characteristics of the implants included in the present study.[27]

In our study, implants placed subcrestally and with two stages protocol exhibited more bone loss but bone change patterns within both groups appeared to be minimal and without clinical significance.

Acknowledgment

The authors would like to thank Dr. Barbara Corso (PhD-National Research Council, Neuroscience Institute, Padova, Italy) is gratefully acknowledged for his support in the statistical analysis.

Financial support and sponsorship

Nil.

Conflicts of interest

There are no conflicts of interest.

REFERENCES

1. Hartman GA, Cochran DL. Initial implant position determines the magnitude of crestal bone remodeling. J Periodontol 2004;75:572-7.
2. Jung RE, Pjetursson BE, Glauser R, Zembic A, Zwahlen M, Lang NP. A systematic review of the 5-year survival and complication rates of implant-supported single crowns. Clin Oral Implants Res 2008;19:119-30.
3. Malchiodi L, Cucchi A, Ghensi P, Bondì V. A case of rapidly progressive peri-implantitis around a short sintered porous-surfaced implant. J Indiana Dent Assoc 2009-2010;88:33-5.
4. Lang NP, Pun L, Lau KY, Li KY, Wong MC. A systematic review on survival and success rates of implants placed immediately into fresh extraction sockets after at least 1 year. Clin Oral Implants Res 2012;23 Suppl 5:39-66.
5. Albrektsson T, Zarb G, Worthington P, Eriksson AR. The long-term efficacy of currently used dental implants: A review and proposed criteria of success. Int J Oral Maxillofac Implants 1986;1:11-25.
6. Wennström JL, Ekestubbe A, Gröndahl K, Karlsson S, Lindhe J. Implant-supported single-tooth restorations: A 5-year prospective study. J Clin Periodontol 2005;32:567-74.
7. Malchiodi L, Ghensi P, Cucchi A, Pieroni S, Bertossi D. Peri-implant conditions around sintered porous-surfaced (SPS) implants. A 36-month prospective cohort study. Clin Oral Impl Res 2015;26:212-9.
8. Albrektsson T, Buser D, Sennerby L. Crestal bone loss and oral implants. Clin Implant Dent Relat Res 2012;14:783-91.
9. Ghensi P, Tonetto G, Soldini C, Bettio E, Mortellaro C, Soldini C. Dental implants with a platform-switched Morse taper connection and an osteo growth induction surface. J Craniofac Surg 2019;30:1049-54.
10. Albrektsson T, Brånemark PI, Hansson HA, Lindström J. Osseointegrated titanium implants. Acta Orthop Scand 1981;52:155-70.
11. Abrahamsson I, Berglundh T, Linder E, Lang NP, Lindhe J. Early bone formation adjacent to rough and turned endosseous implant surfaces. An experimental study in the dog. Clin Oral Implants Res 2004;15:381-92.
12. Albrektsson T, Wennerberg A. Oral implant surfaces: Part 1 – Review focusing on topographic and chemical properties of different surfaces and *in vivo* responses to them. Int J Prosthodont 2004;17:536-43.
13. Wennerberg A, Albrektsson T, Andersson B. Bone tissue response to commercially pure titanium implants blasted with fine and coarse particles of aluminum oxide. Int J Oral Maxillofac Implants 1996;11:38-45.
14. Ghensi P, Bressan E, Gardin C, Ferroni L, Soldini MC, Mandelli F, *et al*. The biological properties of OGI surfaces positively act on osteogenic and angiogenic commitment of mesenchymal stem cells. Materials (Basel) 2017;10:E1321.
15. Ghensi P, Bressan E, Gardin C, Ferroni L, Ruffato L, Caberlotto M, *et al*. Osteo Growth Induction titanium surface treatment reduces ROS production of mesenchymal stem cells increasing their osteogenic commitment. Mater Sci Eng C Mater Biol Appl 2017;74:389-98.
16. Jansen VK, Conrads G, Richter EJ. Microbial leakage and marginal fit of the implant-abutment interface. Int J Oral Maxillofac Implants 1997;12:527-40.
17. Caricasulo R, Malchiodi L, Ghensi P, Fantozzi G, Cucchi A. The influence of implant-abutment connection to peri-implant bone loss: A systematic review and meta-analysis. Clin Implant Dent Relat Res 2018;20:653-64.
18. Koutouzis T, Wallet S, Calderon N, Lundgren T. Bacterial colonization of the implant-abutment interface using an *in vitro* dynamic loading model. J Periodontol 2011;82:613-8.
19. Gardner DM. Platform switching as a means to achieving implant esthetics. N Y State Dent J 2005;71:34-7.
20. Lazzara RJ, Porter SS. Platform switching: A new concept in implant dentistry for controlling postrestorative crestal bone

levels. Int J Periodontics Restorative Dent 2006;26:9-17.
21. Prosper L, Redaelli S, Pasi M, Zarone F, Radaelli G, Gherlone EF. A randomized prospective multicenter trial evaluating the platform-switching technique for the prevention of postrestorative crestal bone loss. Int J Oral Maxillofac Implants 2009;24:299-308.
22. Vandeweghe S, De Bruyn H. A within-implant comparison to evaluate the concept of platform switching: A randomised controlled trial. Eur J Oral Implantol 2012;5:253-62.
23. Fernández-Formoso N, Rilo B, Mora MJ, Martínez-Silva I, Díaz-Afonso AM. Radiographic evaluation of marginal bone maintenance around tissue level implant and bone level implant: A randomised controlled trial. A 1-year follow-up. J Oral Rehabil 2012;39:830-7.
24. Telleman G, Raghoebar GM, Vissink A, Meijer HJ. Impact of platform switching on peri-implant bone remodeling around short implants in the posterior region, 1-year results from a split-mouth clinical trial. Clin Implant Dent Relat Res 2014;16:70-80.
25. Caton JG, Armitage G, Berglundh T, Chapple IL, Jepsen S, Kornman KS, *et al*. A new classification scheme for periodontal and peri-implant diseases and conditions – Introduction and key changes from the 1999 classification. J Clin Periodontol 2018;45 Suppl 20:S1-8.
26. Martinez-Canut P, Lorca A, Magán R. Smoking and periodontal disease severity. J Clin Periodontol 1995;22:743-9.
27. Derks J, Schaller D, Håkansson J, Wennström JL, Tomasi C, Berglundh T. Effectiveness of implant therapy analyzed in a Swedish population: Prevalence of peri-implantitis. J Dent Res 2016;95:43-9.
28. Ainamo J, Bay I. Problems and proposals for recording gingivitis and plaque. Int Dent J 1975;25:229-35.
29. Berglundh T, Armitage G, Araujo MG, Avila-Ortiz G, Blanco J, Camargo PM, *et al*. Peri-implant diseases and conditions: Consensus report of workgroup 4 of the 2017 World Workshop on the Classification of Periodontal and Peri-Implant Diseases and Conditions. J Clin Periodontol 2018;45 Suppl 20:S286-91.
30. Schwarz F, Derks J, Monje A, Wang HL. Peri-implantitis. J Periodontol 2018;89 Suppl 1:S267-90.
31. Hermann JS, Buser D, Schenk RK, Schoolfield JD, Cochran DL. Biologic Width around one- and two-piece titanium implants. Clin Oral Implants Res 2001;12:559-71.
32. Quirynen M, van Steenberghe D. Bacterial colonization of the internal part of two-stage implants. An *in vivo* study. Clin Oral Implants Res 1993;4:158-61.
33. Berglundh T, Lindhe J. Dimension of the periimplant mucosa. Biological width revisited. J Clin Periodontol 1996;23:971-3.
34. Dibart S, Warbington M, Su MF, Skobe Z. *In vitro* evaluation of the implant-abutment bacterial seal: The locking taper system. Int J Oral Maxillofac Implants 2005;20:732-7.
35. Dreyer H, Grischke J, Tiede C, Eberhard J, Schweitzer A, Toikkanen SE, *et al*. Epidemiology and risk factors of peri-implantitis: A systematic review. J Periodontal Res 2018;53:657-81.
36. Poli PP, Beretta M, Grossi GB, Maiorana C. Risk indicators related to peri-implant disease: An observational retrospective cohort study. J Periodontal Implant Sci 2016;46:266-76.
37. Wilson TG Jr., Glover ME, Schoen J, Baus C, Jacobs T. Compliance with maintenance therapy in a private periodontal practice. J Periodontol 1984;55:468-73.
38. Monje A, Wang HL, Nart J. Association of preventive maintenance therapy compliance and peri-implant diseases: A cross-sectional study. J Periodontol 2017;88:1030-41.
39. Derks J, Tomasi C. Peri-implant health and disease. A systematic review of current epidemiology. J Clin Periodontol 2015;42 Suppl 16:S158-71.
40. Derks J, Schaller D, Håkansson J, Wennström JL, Tomasi C, Berglundh T. Peri-implantitis – Onset and pattern of progression. J Clin Periodontol 2016;43:383-8.