Marino Caroprese
Claudio Soldini
Sara Ricci
Massimiliano Rea
Niklaus P. Lang
Daniele Botticelli

Healing at implants placed in bone of different morphology: an experimental study in dogs

Authors' affiliations:
Claudio Soldini, Sara Ricci,
Università degli Studi di Padova, Padova, Italy
Marino Caroprese, Massimiliano Rea, Faculty of Dentistry, University of Medical Science, La Habana, Cuba
Niklaus P. Lang, Center for Dental Medicine, University of Zurich, Zurich, Switzerland
Niklaus P. Lang, University of Bern, Bern, Switzerland
Daniele Botticelli, ARDEC Academy, Ariminum Odontologica, Rimini, Italy
POI- Programa Odontológico Internacional, Cartagena de Indias, Colombia

Corresponding author:
Daniele Botticelli, MD, PhD
POI- Programa Odontológico Internacional
Centro Histórico, Av. Venezuela
Edificio City Bank, Piso 5, Oficina 5G
Cartagena de Indias – Colombia
Tel/Fax: 0057/5/6468359
e-mail: daniele.botticelli@ardec.it

Key words: animal study, bone, dental implants, histology, implant dentistry, morphometry

Abstract

Objective: To study osseointegration at implants installed using a standard bed preparation in sites of different bone morphology.

Material and methods: In six Labrador dogs, all mandibular premolars and first molars were extracted. After 4 months of healing, flaps were elevated, and two recipient sites were prepared in each side of the mandible, one in the second premolar and the other in the molar regions. Bone morphology and final insertion torque were evaluated. Healing abutments were applied, and the flaps were sutured to allow a non-submerged healing. After 4 months, the animals were sacrificed and ground sections were obtained for histomorphometric analyses.

Results: At the premolar sites, bone morphology Class 2 and at the molar regions Class 3 or 4 were identified. The final insertion torque was 50–55 Ncm at the premolar and 30–35 Ncm at the molar sites. Mean osseointegration in percentage reached 61.5 ± 11.5% and 63.3 ± 10.1% at the premolar and molar sites, respectively. Mineralized bone density evaluated from the implant surface up to a distance of about 0.6 mm lateral to the implant surface was 63.0 ± 7.4% and 65.4 ± 17.7% at the premolar and molar sites, respectively.

Conclusions: Similar implant bed preparations performed at premolar and molar sites with different bone morphology, yielding insertion torque values of about 30–35 and 50–55 Ncm, respectively, did not affect osseointegration after 4 months at non-submerged implants.

Various factors may influence the dynamics of osseointegration (Botticelli & Lang 2016).

Among them, implant primary stability is considered an important factor for obtaining implant tissue integration. In fact, micromotion of the implant within the recipient bony bed may lead to a failure of osseointegration (Brunski et al. 1979; Quirynen et al. 1992; Isidor 1996, 1997; Lioubavina-Hack et al. 2006). However, an experimental study in dogs (Rea et al. 2015b) has shown that implants installed with an insertion torque close to 0 Ncm and fully submerged may integrate with similar outcomes to those installed at a higher torque.

Primary stability of the implants gained more importance when an immediate load was applied.

It has been suggested that insertion torques of 20–30 Ncm may be sufficient to guarantee the successful osseointegration (Galli et al. 2008). However, a recent clinical study demonstrated that even insertion torque ≤15 Ncm may be sufficient to maintain the stability of 2- and 3-unit bridges after 3 years of loading (Cesaretti et al. 2016).

Applying an early load to the implants may affect bone healing, as shown in the experimental studies (e.g., Stavropoulos et al. 2008; Calvo-Guirado et al. 2014; Rea et al. 2015a). In an experiment in dogs, the healing at implants immediately loaded was compared with that at implants left unloaded (Rea et al. 2015a). A higher osseointegration at the loaded compared to the unloaded sites was observed. Likewise, a higher osseointegration at sites with lower (30 Ncm) compared to higher (>70 Ncm) insertion torques was found. Hence, it was concluded that low torque values may provide better osseointegration than high insertion torque values.

Different torques are obtained at implants installed in sites with different bone morphology. An experimental study in dogs (Pantani et al. 2010) showed that different insertion torque values were obtained at

Date:
Accepted 20 May 2016

To cite this article:
Caroprese M, Soldini C, Ricci S, Rea M, Lang NK, Botticelli D. Healing at implants placed in bone of different morphology: an experimental study in dogs.
Clin. Oral Impl. Res. **00**, 2016, 1–5
doi: 10.1111/clr.12905

© 2016 John Wiley & Sons A/S. Published by John Wiley & Sons Ltd

implants installed in sites prepared in the anterior region of the mandible (second premolar; values range 35–15 Ncm) compared to those installed in the molar region (values range 19–7 Ncm). In that study, final drills with different diameters were used to obtain different insertion torques at both the premolar and molar sites. The recipient sites were prepared deeper than the implant length and a countersink was applied in the coronal aspect of the bony crest. As a result, neither the apex nor the neck of the implants was in primary contact with the bony crest so that the primary stability was ensured only by the pressure resulting from the surface of the implants onto the lateral bony walls of the recipient implant bed. The procedures adopted in the coronal and apical aspects of the recipient sites reduced the torque values to a maximum of 35 Ncm in the premolar region and of 19 Ncm in the molar region.

The aim of the present experiment was to study osseointegration at implants installed using a standard bed preparation in sites with different bone morphology, such as the second premolar and first molar regions.

Material and methods

The research protocol was submitted to and approved by the Ethical Committee of the People's Liberation Army General Hospital, Laboratory Animal Welfare of Beijing, PR of China.

Six Labrador dogs, about 4 years old and 25–26 kg in weight, were used for the experiment. The animals were anesthetized with 3% pentobarbital sodium at any surgical session and kept in intravenous infusion of physiologic saline. Local anesthesia was provided at the experimental sites. Penicillin i.m. 320 i.u. was injected at the time of surgery and 160 i.u. daily afterward for 3 days, together with an analgesic.

First molars and all premolars were extracted bilaterally. Four months afterward, full-thickness flaps were elevated, and two implant sites were prepared to a depth of about 11 mm, one in the premolar and other in the molar regions, and bone morphology classes (Lekholm & Zarb 1985) were identified. Implants, 10 mm long and 4 mm in diameter (CLC Conic; CLC Scientific, Vicenza, Italy), with a large-grit sandblasted and acid etched surface (Ra 1.61 ± 0.31; Fig. 1a-e), were installed with the shoulder placed at the level of the buccal alveolar bony crest (Fig. 2a-d). The final insertion torque was measured with a calibrated wrench (CLC Scientific, Vicenza, Italy; Fig. 2a). Healing abutments were positioned on the top of each implant and the flaps were sutured to allow a non-submerged healing.

An inspection of the treated zones for clinical signs of complications and abutment cleaning was performed 3 times per week for the entire duration of the experiment.

After 4 months of healing, the dogs were sacrificed with an overdose of 3% pentobarbital sodium, and potassium chloride was subsequently administered.

Histological preparation

The mandibles were removed and then maintained in a solution of 4% formaldehyde. Block sections, each containing one implant, were prepared and dehydrated in a series of graded ethanols and subsequently embedded into resin (Technovit® 7200 VLC; Kulzer, Friedrichsdorf, Germany). Each block was cut in a bucco-lingual plane using a diamond band saw fitted in a precision slicing machine (Exakt®; Apparatebau, Norderstedt, Germany). One central section was selected and reduced to a thickness of about 50 μm using a cutting–grinding device (Exakt®). The histological slides were stained with toluidine blue and examined under a standard light microscope for histometric analysis.

Histological evaluation

In an Eclipse C*i* microscope (Nikon Corporation, Tokyo, Japan) equipped with a digital video camera (Nikon mod. DS-Fi1; Nikon Corporation) connected to a computer, the following measurements were performed using the software NIS-Elements (Nikon Corporation) at a magnification of ×100:

(i) Mineralized bone-to-implant contact (MBIC), measured from the most coronal contact of bone to the implant surface (B) to the apex of the implant, both at the buccal and lingual aspects. The total MBIC% was subsequently calculated in relation to the extension of the implant surface evaluated.

(ii) The percentage of mineralized bone around the implant surface form B to the apex of the implant, up to a distance of about 0.6 mm lateral to the implant surface. For this purpose, a point counting procedure was used to determine the hard and soft tissue compositions (Schroeder & Münzel-Pedrazzoli 1973). A lattice was superposed over the tissues, and the percentages of mineralized bone were evaluated.

Data analysis

Mean values and standard deviations (SD) as well as 25th, 50th (median), and 75th



Fig. 1. Details of the surface microtopography at the SE: coronal zone at a magnification of (a) ×50, (b) ×500, (c) ×2000. (d) Median and (e) apical zones at ×2000 magnification.

© 2016 John Wiley & Sons A/S. Published by John Wiley & Sons Ltd

percentiles were calculated for each outcome variable.

The data from the right and left side of the mandible at the premolar region were pooled together as well as those from the molar region. The means obtained at the premolar and molar sites were used for statistical analyses. The Wilcoxon test was applied for statistical analysis using the IBM SPSS Statistics (v. 19; IBM Inc. Chicago, IL, USA). The level of significance was set at $\alpha = 0.05$.

Results

Clinical evaluation

The final insertion torque at the premolar sites was 50–55 Ncm, while at the molar sites, it was 30–35 Ncm.

The bone morphology was classified as Class 2 at the premolar sites and Class 3 at molar sites, with the exception of one side in one dog that was classified as Class 4.

Histological evaluation

Data of soft tissue and marginal hard tissue healing are reported elsewhere (Rea et al. 2016).

All implants were integrated and available for the histological assessment so that an $n = 6$ was obtained for all evaluations.

Table 1 reports data on mineralized bone-to-implant contact and morphometry. Only mean values ± SD are reported in the text.

At the histological analysis, the implants appeared to be well integrated, surrounded by mature mineralized bone and bone marrow at both premolar and molar sites (Fig. 3a-d and Fig. 4a-d). MBIC% yielded a percentage of 61.5 ± 11.5% (MBIC%) at the premolar sites and of 63.3 ± 10.1% at the molar sites, respectively (Table 1; Fig. 5). The difference between premolar and molar regions did not reach statistical significance.

Bone morphometry evaluation at the premolar sites yielded a percentage of mineralized bone of 63.0 ± 7.4%, whereas at molar sites, it reached a percentage of 65.4 ± 17.7% (Table 1; Fig. 5). Again, the difference between premolar and molar sites was not statistically significant.

Discussion

In the present study, the healing after 4 months following implant installation in bone with different morphology (according to Lekholm & Zarb 1985) was evaluated.

This difference was substantiated by a difference in the final insertion torque that was 50–55 Ncm at the premolar and 30–35 Ncm at the molar regions. It has to be considered that the torque was reflecting the lateral pressure of the implant on the bony walls of the recipient sites. In fact, the sites were prepared deeper than the extension of the implant to eliminate any interference produced by a possible impact of the tip of the implant toward the alveolar bone.

Despite the difference in bone morphology, similar percentages of mineralized bone-to-implant contact were found, with 61.5 ± 11.5% and 63.3 ± 10.1% at the premolar and molar regions, respectively. These differences did not reveal statistical significance.

The outcome from the present experiment is in agreement with results from another experiment in dogs where the healing at fully submerged implants installed in the premolar or molar regions were studied (Pantani et al. 2010). Also in that experiment, the sites were prepared deeper than the length of the implants, both apically and at the level of the neck of the implant, so that only lateral pressure was influencing the final insertion torque. At both the premolar and molar regions, one site was prepared using a 0.2-mm narrower final drill compared to the contralateral side. The differences in bone morphology and bed preparation yielded four different groups based on the final insertion torques, which had values of about 36 Ncm and 15 Ncm at the premolar sites and 19 Ncm and 7 Ncm at the molar sites, the former being the highest values related to the bed prepared with the narrower drills.

Despite the differences between groups, after 4 months of healing, no statistically significant differences were found in mineralized bone-to-implant contact between groups, the values ranging between from 49 to 59%.

Another study reported the outcomes of implants installed in edentulous premolar/molar regions (Rea et al. 2015a,b). In one side of the mandible, the recipient sites were prepared with either standard or 0.2-mm-wide drills. At the standard sites, a final insertion torque of about 30 Ncm was obtained, while

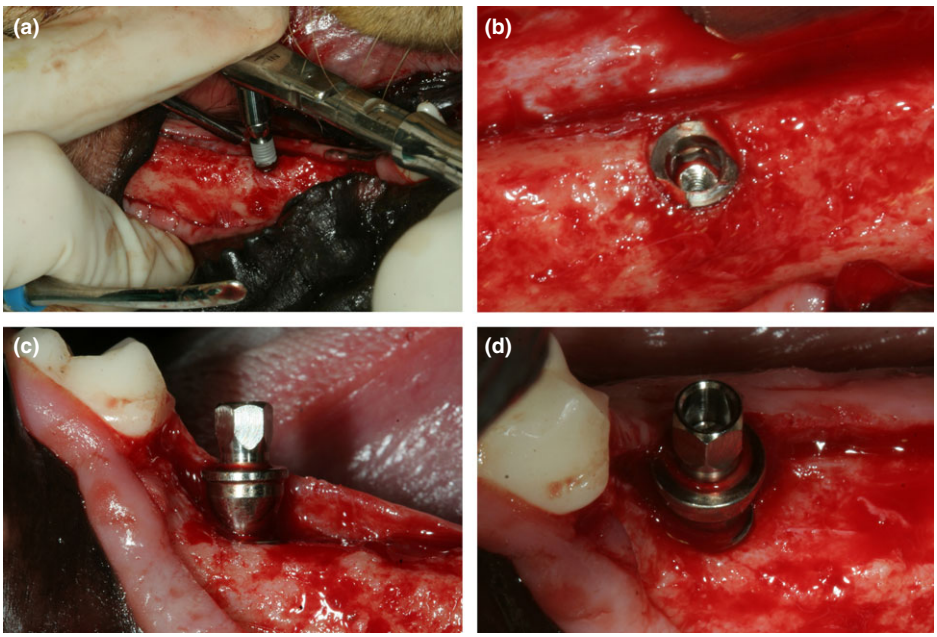

Fig. 2. (a) Second premolar region. The implants were installed using a calibrated wrench and the final insertion torque was recorded. (b) Second premolar region. The implants were installed with the shoulder placed flush to the buccal alveolar bony crest. (c-d) Implant installed in the first molar region. The mounter is still in place.

Table 1. **Mineralized bone-to-implant contact (MBIC %) and mineralized bone density (MB%). ($n = 6$)**

	MBIC%		MB%	
	Premolar	Molar	Premolar	Molar
Mean (SD)	**61.5** (11.5)	**63.3** (10.1)	**63.0** (7.4)	**65.4** (17.7)
Median (25th; 75th)	**63.9** (53.9; 68.6)	**62.8** (56.8; 72.0)	**62.1** (58.5; 65.7)	**71.0** (51.7; 79.3)

Mean values (in bold) (SD = standard deviations) and medians (in bold) (25th and 75th percentiles). $P < 0.05$. None of the differences were statistically significant.

© 2016 John Wiley & Sons A/S. Published by John Wiley & Sons Ltd

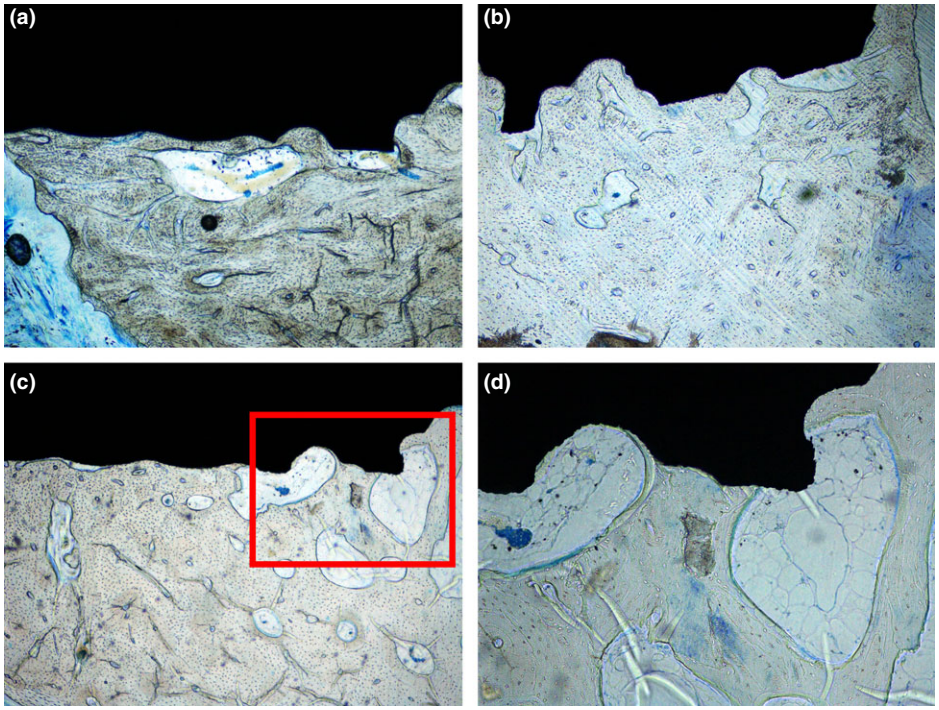

Fig. 3. Premolar sites. Ground sections illustrating examples of healing at the (a) marginal and (b) apical area of the implant. (c) Mineralized bone as well as bone marrow spaces in close contact with the implant surface. Original magnification ×40. (d) Higher magnification (×100) of the area contained in the red framework in (c). Toluidine blue stain.

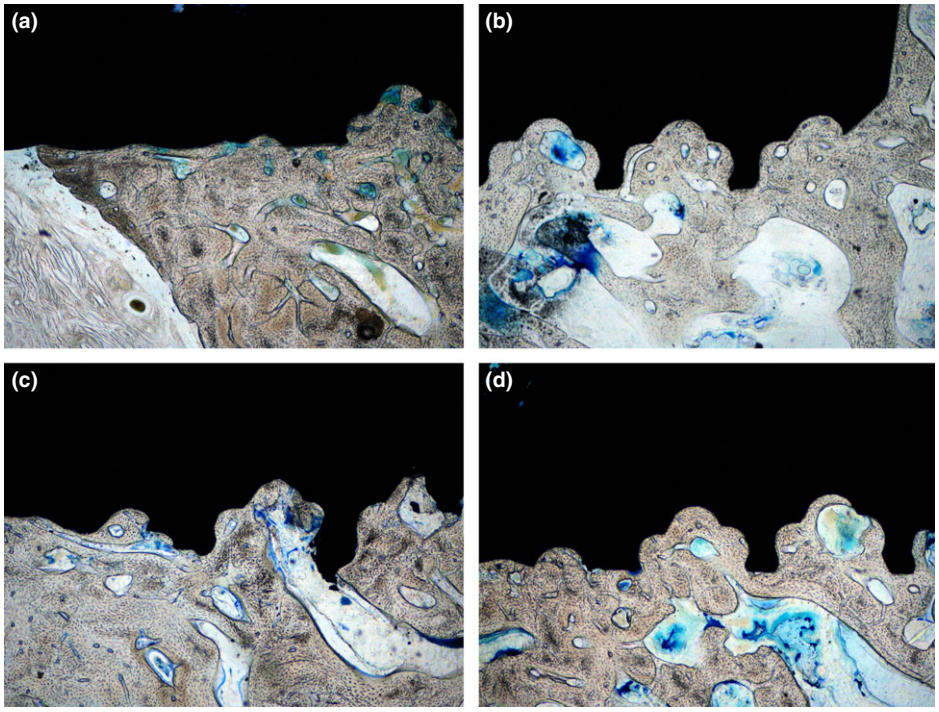

Fig. 4. Molar sites. Ground sections illustrating examples of healing at the (a) marginal, apical (b) and central (c-d) area of the implants. Original magnification ×40. Toluidine blue stain.

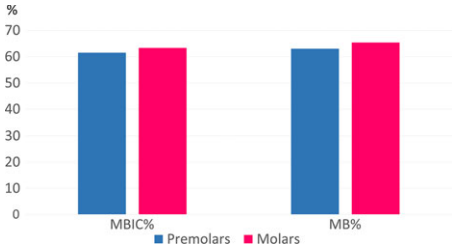

Fig. 5. Graphic illustrating the percentages of mineralized bone-to-implant contact (MBIC%) and mineralized bone density (MB) at the premolar and molar sites. Similar values were found.

at the wider sites, a torque close to 0 was registered. In the contralateral side, two sites were prepared with drills 0.3 mm narrower in diameter compared to the standard sites so that a torque ≥70 Ncm resulted. A submerged healing was allowed and after 4 months, biopsies were harvested for histological evaluation. The range of mineralized bone-to-implant contact was 55.2–62.1%, presenting the lowest values at the sites with torques close to 0. However, there were no statistically significant differences in the percentages of mineralized bone-to-implant contact.

The studies described above presented similar outcomes to those reported in this study and are related to torques from close to 0 to ≥70 Ncm. This, in turn, means that the final insertion torque did not yield a great impact on bone-to-implant contact.

Another experiment, however, studied the healing at implants installed in the mandibles of five sheep applying a torque of either 110 Ncm or 10 Ncm (Trisi et al. 2011). One sheep was sacrificed at each of the following observation periods: 1, 2, 3, 4, and 6 weeks. After 6 weeks of healing, within the cortical region, a higher percentage of bone-to-implant contact and a higher removal torque were found at the high (~71% and 61 Ncm) compared to the low (~64% and 40 Ncm) torque sites. Despite the very low sample of animals used per period ($n = 1$), this outcome indicated that, even using very high insertion torques, a good implant tissue integration might have resulted.

In this study, the morphometric analyses revealed a percentage of mineralized bone similar to premolar (63.0%) and molar (65.4%) sites. No statistically significant differences were found between the different morphologies. This outcome confirmed that position and final insertion torques did not affect the osseointegration, when a standard bed preparation was applied and a final insertion torque between 30 and 55 Ncm was applied. In a study previously described (Pantani et al. 2010), a higher density of mineralized bone was found at the premolar compared to the molar regions, even though no statistically significant differences were revealed. This was related to the fact that the proximity of the implant surface to the cortical plates of the mandible differed at the two

© 2016 John Wiley & Sons A/S. Published by John Wiley & Sons Ltd

regions, being closer to the premolar compared to the molar regions. Moreover, in that study, bone morphometry evaluation was extended to 1 mm from the implant surface, fact that included larger portion of the cortical plate at the premolar compared to the molar regions. In this study, however, the examination was reduced to 0.6 mm from the implant, in order to decrease the chance of including the pristine cortical plates within the evaluation.

In conclusion, similar implant bed preparations performed at premolar and molar sites with different bone morphology, yielding different insertion torque values of about 30–35 and 50–55 Ncm, respectively, did not affect osseointegration after 4 months at non-submerged implants.

Acknowledgements: This study has been supported by CLC Scientific, Vicenza, Italy, by ARDEC Academy, Ariminum Odontologica SRL, Rimini, Italy, and by the Clinical Research Foundation (CRF) for the Promotion of Oral Health, CH-3855 Brienz, Switzerland.

Conflicts of interests

Dr Claudio Soldini declares a conflict of interest with the implant brand used in this study as co-owner for the company CLC Scientific. All the other authors declare no conflict of interest.

References

Botticelli, D. & Lang, N.P. (2016) Dynamics of osseointegration in various human and animal models- A comparative analysis. Accepted for publication in *Clinical Oral Implants Research* doi: 10.1111/clr.12872. [Epub ahead of print].

Brunski, J.B., Moccia, A.F., Jr, Pollack, S.R., Korostoff, E. & Trachtenberg, D.I. (1979) The influence of functional use of endosseous dental implants on the tissue-implant interface. I. Histological aspects. *Journal of Dental Research* **58**: 1953–1969.

Calvo-Guirado, J.L., Aguilar-Salvatierra, A., Gomez-Moreno, G., Guardia, J., Delgado-Ruiz, R.A. & Mate-Sanchez de Val, J.E. (2014) Histological, radiological and histomorphometric evaluation of immediate vs. non-immediate loading of a zirconia implant with surface treatment in a dog model. *Clinical Oral Implants Research* **25**: 826–830.

Cesaretti, G., Botticelli, D., Renzi, A., Rossi, M., Rossi, R. & Lang, N.P. (2016) Radiographic evaluation of immediately loaded implants supporting 2-3 units fixed bridges in the posterior maxilla: a 3-year follow-up prospective randomized controlled multicenter clinical study. *Clinical Oral Implants Research* **27**: 399–405.

Galli, F., Capelli, M., Zuffetti, F., Testori, T. & Esposito, M. (2008) Immediate non-occlusal vs. early loading of dental implants in partially edentulous patients: a multicentre randomized clinical trial. Peri-implant bone and soft-tissue levels. *Clinical Oral Implants Research* **19**: 546–552.

Isidor, F. (1996) Loss of osseointegration caused by occlusal load of oral implants. A clinical and radiographic study in monkeys. *Clinical Oral Implants Research* **7**: 143–152.

Isidor, F. (1997) Histological evaluation of peri-implant bone at implants subjected to occlusal overload or plaque accumulation. *Clinical Oral Implants Research* **8**: 1–9.

Lekholm, U. & Zarb, G.A. (1985) Patient selection and preparation. In: Brånemark, P.I., Zarb, G.A. & Albrektsson, T., eds. Tissue-Integrated Prostheses: Osseointegration in Clinical Dentistry, 199–208. Chicago: Quintessence.

Lioubavina-Hack, N., Lang, N.P. & Karring, T. (2006) Significance of primary stability for osseointegration of dental implants. *Clinical Oral Implants Research* **17**: 244–250.

Pantani, F., Botticelli, D., Garcia, I.R., Jr, Salata, L.A., Borges, G.J. & Lang, N.P. (2010) Influence of lateral pressure to the implant bed on osseointegration: an experimental study in dogs. *Clinical Oral Implants Research* **21**: 1264–1270.

Quirynen, M., Naert, I. & van Steenberghe, D. (1992) Fixture design and overload influence marginal bone loss and fixture success in the Brånemark system. *Clinical Oral Implants Research* **3**: 104–111.

Rea, M., Botticelli, D., Ricci, S., Soldini, C., González, G.G. & Lang, N.P. (2015a) Influence of immediate loading on healing of implants installed with different insertion torques–an experimental study in dogs. *Clinical Oral Implants Research* **26**: 90–95.

Rea, M., Lang, N.P., Ricci, S., Mintrone, F., González González, G. & Botticelli, D. (2015b) Healing of implants installed in over- or under-prepared sites–an experimental study in dogs. *Clinical Oral Implants Research* **26**: 442–446.

Rea, M., Ricci, S., Ghensi, P., Lang, N.P., Botticelli, D. & Soldini, C. (2016) Marginal healing using Polyetheretherketone (PEEK) as healing abutments. An experimental study in dogs. Accepted for publication in *Clinical Oral Implants Research* doi: 10.1111/clr.12854. [Epub ahead of print].

Schroeder, H.E. & Münzel-Pedrazzoli, S. (1973) Correlated morphometric and biochemical analysis of gingival tissue. Morphometric model, tissue sampling and test of stereologic procedures. *Journal of Microscopy* **99**: 301–329.

Stavropoulos, A., Nyengaard, J.R., Lang, N.P. & Karring, T. (2008) Immediate loading of single SLA implants: drilling vs. osteotomes for the preparation of the implant site. *Clinical Oral Implants Research* **19**: 55–65.

Trisi, P., Todisco, M., Consolo, U. & Travaglini, D. (2011) High versus low implant insertion torque: a histologic, histomorphometric, and biomechanical study in the sheep mandible. *The International Journal of Oral Maxillofacial Implants* **26**: 837–849.

© 2016 John Wiley & Sons A/S. Published by John Wiley & Sons Ltd